

KEEP AN EYE ON YOUR SIGHT



**INFORMATION
FOR PEOPLE
WITH DIABETES**





Page 3

1

**¿What is
diabetic
retinopathy?**

Page 4

2

**Types of
retinopathy**

Page 5

3

Symptoms

Page 5

4

Causes

Page 6

5

Diagnosis

Page 7


6

Treatment

Page 10

7

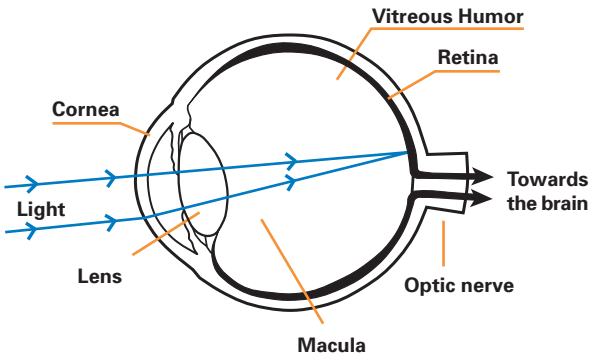
**Other
diseases**



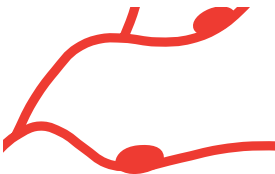➔ [Back to INDEX](#)

¿What is diabetic retinopathy?

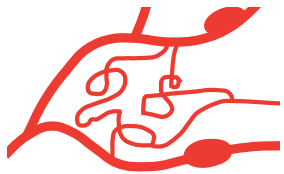The retina is the part of the eye onto which light filtered through the lens is focused. The light or images stimulate the nerve endings of the retina, generating a series of electric pulses that are then transmitted to the brain along the optic nerve.



The retina is a layer of nerves located in the posterior region of the eye, which records images in the way of a photographic camera. The retina contains very fine blood vessels that provide it with required nutrients. Retinopathy develops when these vessels are damaged.



Diabetic retinopathy of the fundus (or early stage disease)



Diabetic retinopathy Proliferating (or advanced)

After 10 years of suffering from diabetes, 50% of patients have some degree of retinopathy – a percentage that increases to 80% after 15 years.



➔ [Back to INDEX](#)

2

Types of retinopathy

There are **3 types** of retinopathy:

Non-proliferative retinopathy

Also known as fundus retinopathy, this is the least serious form of the disease. The arteries are frequently dilated (forming microaneurysms) or lose some fluid within the retina; as a result, the latter becomes inflamed or deposits known as exudates develop.


Maculopathy occurs when fluid escape affects the blood vessels surrounding the macula (the zone of the retina responsible for central vision and greatest visual acuity); this may produce macular edema and severely compromise visual acuity. In fact, in type 2 diabetes this is the most common cause of diminished visual acuity.

Pre-proliferative retinopathy

This represents a more advanced stage, where certain lesions exist, such as cottony exudates, dilated and tortuous retinal capillaries, and venous sheathing. When these signs arise, the risk of proliferative retinopathy is greatly increased.

Proliferative retinopathy

This is the most serious form of the disease, though fortunately it is also the least common: it may affect between 20% and 25% of all diabetics. In these cases the retinal arteries are so damaged that some are even occluded - a phenomenon that in turn leads to the appearance of abnormal blood vessels that often cause bleeding and severely deteriorate visual acuity. Repeated abnormal proliferation of this type may cause opacification of the vitreous humor (a normally transparent jelly-like substance that fills the eyeball), blocking the passage of light through the pupil towards the retina.



➔ [Back to INDEX](#)

In other cases these abnormal blood vessels trigger the formation of fibrous tissue that may stretch and retract the retina, causing it to detach from the fundus (a phenomenon known as retinal detachment) and producing severe loss of vision if not treated on time. However, at present it is possible to treat even proliferative retinopathy and thus prevent blindness.

3

Symptoms

In most cases THERE ARE NO SYMPTOMS – not only in the early stages of the disease but even once proliferative retinopathy has developed. In other cases – particularly if the region of the macula is affected – blurry vision may develop, especially in the morning. No clear explanation has yet been found for this.

The fact that the condition so frequently generates no symptoms makes it very important to visit the ophthalmologist yearly.

4

Causes

Diabetic retinopathy is a complex disease, and though much is known of its natural course, the underlying causes of the process have not been clearly defined. However, the disease is generally thought to be triggered by a combination of biochemical, metabolic and hematological alterations, as outlined below.

■ **Hyperglycemia.** When chronic, hypoglycemia can alter the metabolism of the retinal vascular cells.

■ **Alterations of the Platelets.** Possibly, biochemical alterations generated by diabetes may induce excess platelet aggregation.



➔ [Back to INDEX](#)

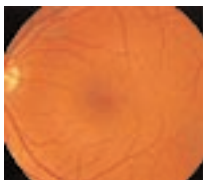■ **Blood vessel narrowing (stenosis).** This phenomenon is caused by hematological alterations.

These factors all alter the arrival of nutrients in the retina, with fluid escape from the blood vessels and triggering of the disease process.

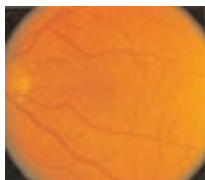
5

Diagnosis

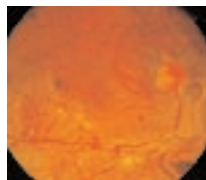
An early diagnosis is essential. In order to detect the presence of retinopathy, the ophthalmologist examines the interior of the eye with an instrument called an ophthalmoscope, after dilating the pupils with a few eyedrops. A careful slit-lamp ophthalmoscopic examination of the macular area is also important, as the ophthalmoscope alone is unable to directly visualize a macular edema (though it may be suspected if hardened exudates are detected in the vicinity of the macular region).



Norma lRetina




Fundus Retinopathy



Proliferative Retinopathy

In addition, in certain cases, if the ophthalmologist observes some alteration, he or she may wish to perform other special tests such as angiofluoresceinography (AFG).

AFG consists of the injection of a fluorescent dye into the arm of the patient, after which a series of special photographs are made of the eyes to reveal the blood vessel walls and identify possible zones of poor retinal vascularization. The technique is painless, though somewhat bothersome because of the camera flash. Allergic patients should report their allergy to the ophthalmologist.



➔ [Back to INDEX](#)

Most frequent indications of AFG:

- Before commencing a photocoagulation session, to help pin-point the laser-light irradiation zones.
- After 10 years of diabetes, even if the fundus examination is normal.
- On planning pregnancy or in the early stages of pregnancy.
- Systematically, in those diabetic patients who have lost vision in one eye (of whatever cause).
- On the indication of the ophthalmologist after he or she has observed some suspect lesion (for example, pre-proliferative alterations).

The patient should not be alarmed if blurry vision, transient nausea or yellowish urine appear after AFG.

The patient should be aware that for a few hours after dilating the pupils he or she will not be able to drive, and should moreover wear sunglasses to protect the eyes and avoid discomfort caused by the excess exposure to light.

Additional tests that may be performed are tonometry, by which intraocular pressure is measured to discard possible glaucoma, etc.



Treatment

In many cases treatment is not required, though periodic eye examinations are nevertheless necessary.

In other cases treatment is recommended to detain the advance of the lesions caused by diabetic retinopathy and, if possible, improve the quality of eyesight.



➔ [Back to INDEX](#)

■ **DIABETOLOGICAL EDUCATION.**

By means (for example) of informative booklets such as the present. In this sense, it should be remembered that ignorance is the main ally of all the complications of diabetes mellitus.

■ **MAINTENANCE OF GOOD GLYCEMIA CONTROL.**

It is now known that the risk of developing some form of retinopathy can be reduced 60% by maintaining blood glucose (sugar) levels as "normal" as possible. Sometimes, when metabolic control has been very deficient, the diabetologist may recommend a slower adjustment process, for it has been found that sudden adjustment can cause a temporary worsening of the retinopathy.

■ **CONTROL OF ARTERIAL PRESSURE.**


Such control is very important in hypertensive diabetics, as high blood pressures can worsen diabetic retinopathy.

■ **AVOIDANCE OF CERTAIN FORMS OF PHYSICAL EXERCISE**


Physical activities that tend to increase intraocular pressure (such as lifting weights, etc.) should be avoided.

Laser therapy

This therapeutic modality consists of laser light irradiation of the eye (a process known as photocoagulation). A high-energy light beam irradiates the retina through the pupil, causing hundreds of minute burns on the retina, and destroying the growing blood vessels found in patients with proliferative retinopathy.



Up to 90% of patients with proliferative retinopathy can save their eyesight if adequate treatment is provided.



➔ [Back to INDEX](#)

Photocoagulation is also successfully used to treat macular edema. In this case the beam is directly aimed at the blood vessels responsible for blood leakage in the macular zone, to seal the vessels and thus detain the sight-damaging leakage. This is the reason or indication for laser therapy in 60% of all type 2 diabetics.

In some cases the procedure may cause a little pain – though never too much. In any case, the pain produced depends on the retinal zone treated and on individual patient sensitivity.

Other secondary effects of photocoagulation are blurry vision. However, this effect generally lasts only a few days, after which vision returns to its state prior to treatment. In some cases, after many treatment sessions, a certain degree of lateral vision loss can occur.

Cryotherapy

When the vitreous humor is turbid due to the presence of blood, laser therapy cannot be applied until the blood either sediments or is eliminated.

In some cases of vitreous hemorrhage, cryotherapy (or freezing) can reduce the presence of anomalous blood vessels.

Vitrectomy

This surgical procedure is indicated in certain cases of advanced proliferative retinopathy, particularly in the presence of vitreous hemorrhage.

In this technique the ophthalmologist extracts the blood-filled vitreous humor and replaces it with a sterile, transparent solution, while at the same time removing the fibrous tissue from the retina.

About 65% of patients subjected to this technique in a specialized center experience some improvement in eyesight, and at least 20% are able to stabilize vision.

Retinal repair

If the traction exerted upon the fibrous tissue formed in the retina causes the latter to become deta-



➔ [Back to INDEX](#)

ched from the fundus, severe loss of vision may result – unless surgical measures are immediately adopted to reinsert the retina.

Medication

Many drugs have been tested, such as platelet antiaggregating agents, venodilators, aldose-reductase inhibitors, antioxidants, and so on. However, to date no conclusive results have been obtained concerning their potential usefulness.

It can be stated that we are in the beginnings of a new "ERA OF HOPE", in which serious ocular lesions that can even lead to blindness are a thing of the past - thanks to the generalization of preventive measures and advances in the different treatment modalities.



Other diseases


GLAUCOMA AND CATARACTS. Both are found in diabetics with a frequency twice that observed in the non-diabetic population.

Glaucoma

This disease is frequently associated to diabetes, but is not actually caused by it.

Small changes occur in the eye that gradually interfere with normal fluid flow within the eye. If these fluids are unable to drain correctly, intraocular pressure rises, compressing the optic nerve and possibly causing a decrease in visual acuity.

The most common form is a slow and asymptomatic process that is diagnosed once the patient has already suffered important loss of eyesight. In this



➔ [Back to INDEX](#)

sense, emphasis is once again placed on the need for periodic ophthalmologic examinations.

■ **Treatment.** The management of glaucoma normally involves eyedrops that must be applied daily at the same hour. Administration must NEVER be suspended without permission from the ophthalmologist.

A laser-based treatment modality has recently been developed, and after a follow-up period of 7 years, it has been found to be as effective as treatment with eyedrops, i.e., it may constitute an alternative treatment for glaucoma.

Cataracts

Cataracts are likewise not caused by diabetes, though they are more common in diabetics than in non-diabetic persons, and moreover appear at earlier ages.

This disease involves the gradual opacification of the lens, as a result of which visual acuity decreases.

■ **Treatment.** Management is surgical, and consists of the extraction of the opaque lens, which is replaced by a synthetic lens

When to visit the ophthalmologist

- Annually after diagnosis in the case of type 2 diabetes.
- Annually after the fifth year in type 1 diabetes.
- Before planning pregnancy, and then at least every three months in the course of pregnancy.
- Follow-up intervals of under one year may be recommended by the ophthalmologist if lesions requiring closer vigilance are suspected.